2022 Abstracts

Use of Lidocaine/Propofol Mixture to Reduce Burning Upon Injection

Rohan R. Shah[1], BA, Shaul Cohen[2], MD, Danielle Levin[3], MD, Geza Kiss[2],MD

[1] Rutgers New Jersey Medical School, Newark, NJ, USA
[2] Rutgers Robert Wood Johnson Medical School, New Brunswick, NJ, USA
[3] St. Elizabeth's Medical Center, Boston, MA, USA

Presenter: Rohan R. Shah, rs1520@njms.rutgers.edu
Shaul Cohen, cohensh@rwjms.rutgers.edu
Danielle Levin, daniellelevinmd@gmail.com
Geza Kiss, kissgk@rwjms.rutgers.edu

ABSTRACT

Introduction: Propofol is a common medication used for anesthesia induction and is frequently associated with a local burning sensation. IV lidocaine has been shown to attenuate this sensation.

Objective: To determine whether a mixture of lidocaine with propofol for IV induction is superior to IV lidocaine injection before propofol induction for attenuation of pain.

Methods: In this IRB approved retrospective study, 2 groups (ASA I-II) were included. Group 1 patients (n=103) received IV lidocaine followed by IV propofol for induction. Group II patients (n=82) received a mixture of 60 mg lidocaine in 200 mg propofol. Data collected for comparison included age, height, weight, ASA physical status, IV site (back of hand, forearm, antecubital fossa), angiocath size (22, 20, 18), pain score upon injection of propofol (0-10, 10 = utmost severe pain), total propofol induction dose, and total lidocaine dose. A confidence interval of 95% with a p value <0.05 was considered statistically significant. Chi-squared test and t test were used as appropriate.

Discussion: When IV lidocaine was administered before propofol, patients received more lidocaine but reported higher pain scores and more patients reported pain. The mechanism by which propofol causes this burning pain is largely unknown. One theory suggests that the pain stems from afferent nerve endings within the walls of the vein [1], while another suggests that the pain is caused by activation of the kinin cascade in plasma, primarily leading to production and release of bradykinin [2]. The former is the basis for which pretreatment of lidocaine is utilized. Alternatively, the rationale for mixing lidocaine with propofol is based on the idea that lidocaine may act as a stabilizer of the kinin cascade [2]. Another possible mechanism is that mixing the two agents decreases the pH of propofol, resulting in a lower concentration of propofol in its aqueous phase and subsequently less pain [3].

Results: There were no differences among the groups with respect to age, weight, height, or total propofol induction dose. There were also no differences in pain scores for the various IV injection sites and various angiocath sizes. Group 1 received more IV lidocaine but had higher pain score and more patient reported pain during administration of IV propofol.

References:

1.Klement W, et al. Brit J Anaes, 1991; 66:189-95
2. Scott RPF, et al. Anaesthesia, 1988; 43:492-494
3. Eriksson M, et al. Brit J Anaes, 1997; 78:502-6

Neonate Gender's Influence on Intra-Cesarean Nausea and Vomiting

Rohan R. Shah[1], BA, Shaul Cohen[2], MD, Danielle Levin[3], MD

[1] Rutgers New Jersey Medical School, Newark, NJ, USA
[2] Rutgers Robert Wood Johnson Medical School, New Brunswick, NJ, USA
[3] St. Elizabeth's Medical Center, Boston, MA, USA

Presenter: Rohan R. Shah, rs1520@njms.rutgers.edu
Shaul Cohen, cohensh@rwjms.rutgers.edu
Danielle Levin, daniellelevinmd@gmail.com

Abstract

Introduction: Approximately 73-80% of parturients who undergo cesarean section under regional anesthesia experience intraoperative nausea.[1-2] Not only is nausea an unpleasant physical condition, but intraoperative vomiting can cause additional challenges, such as inadvertent surgical trauma, increased risk of bleeding, and aspiration pneumonitis.[3-4] Various prophylactic antiemetic medications exist, but they are not entirely effective and may have multiple adverse effects. Thus, knowing which parturients are at a higher risk of experiencing intraoperative nausea and vomiting could help anesthesiologists provide appropriate prophylactic antiemetic management. Semizet *et al*.[5] suggested that parturients who have a female neonate have a significantly higher rate of intraoperative nausea and vomiting than parturients who have a male neonate. To our knowledge, no other study has yet validated these findings. The goal of our retrospective study was to compare the rate of nausea and vomiting experienced by parturients undergoing cesarean section under combined spinal-epidural anesthesia who had female neonates with those that had male neonates.

Methods: Following IRB approval, 195 parturients who underwent elective cesarean section under combined spinal-epidural anesthesia between 09/2016 and 06/2019 were analyzed. Group I (n = 99) had male neonates, and Group II (n = 96) had female neonates. The rate of nausea and vomiting were compared between the two groups. Excel version 2013 was used for Chi-squared test and Student T-test analysis of our data.

Results: The rate of intraoperative vomiting was also similar between the two groups (Group I - 32.3%, Group II - 30.2%, P = 0.75)

Discussion: In our cohort of parturients, the gender of the neonate did not appear to have a significant effect on whether a parturient experienced intra-cesarean nausea or vomiting. Based on our findings, we were unable to validate Semizet *et al.'s*[5] results. We will continue to explore other risk factors that may

contribute to intra-cesarean nausea and vomiting to further improve parturient satisfaction and safety during delivery.

References:

1. Levin D, Cohen S, Mellender S, et al. Effectiveness of P6 Stimulation for Reduction of Nausea and Vomiting During Caesarean Section Under Combined Spinal-Epidural Anaesthesia: A Randomised Controlled Trial. *Turk J Anaesthesiol Reanim.* 2019;47(2):120-127.

2. Lussos SA, Bader AM, Thornhill ML, Datta S. The antiemetic efficacy and safety of prophylactic metoclopramide for elective cesarean delivery during spinal anesthesia. *Reg Anesth.* 1992;17(3):126-130.

3. Griffiths JD, Gyte GM, Paranjothy S, Brown HC, Broughton HK, Thomas J. Interventions for preventing nausea and vomiting in women undergoing regional anaesthesia for caesarean section. *Cochrane Database Syst Rev.* 2012(9):Cd007579.

4. Bremner WG, Kumar CM. Delayed surgical emphysema, pneumomediastinum and bilateral pneumothoraces after postoperative vomiting. *Br J Anaesth.* 1993;71(2):296-297.

5. Semiz A, Akpak YK, Yilanlioglu NC, et al. Prediction of intraoperative nausea and vomiting in caesarean delivery under regional anaesthesia. *J Int Med Res.* 2017;45(1):332-339.

6. Tognoni P, Simonato A, Robutti N, et al. Preoperative risk factors for postoperative delirium (POD) after urological surgery in the elderly. *Arch Gerontol Geriatr.* 2011;52(3):e166-169.

Stylet Reinsertion to Reduce Incidence of Dural Puncture

Rohan R. Shah[1], BA, Shaul Cohen[2], MD, Danielle Levin[3], MD, Geza Kiss[2] ,MD

[1] Rutgers New Jersey Medical School, Newark, NJ, USA
[2] Rutgers Robert Wood Johnson Medical School, New Brunswick, NJ, USA
[3] St. Elizabeth's Medical Center, Boston, MA, USA

Presenter: Rohan R. Shah, rs1520@njms.rutgers.edu
Shaul Cohen, cohensh@rwjms.rutgers.edu
Danielle Levin, daniellelevinmd@gmail.com
Geza Kiss, kissgk@rwjms.rutgers.edu

ABSTRACT

Introduction:

We noticed that in some patients who complained of paresthesia upon advancement of the epidural needle by the resident, when the stylet was reinserted, a constant jet flow of CSF followed. These residents reported that they felt a "pop" suggesting entry into the epidural space. However, advancement of the needle was continued because a loss-of-resistance (LOR) to air injections was not achieved. On several other occasions when it was suspected that a resident entered the space without losing resistance, the stylet was inserted, and LOR was achieved without further advancing the needle. We speculate that a blood clot and/or a flap of the pierced ligament occluded the lumen of the needle.

Objective:

To determine whether stylet reinsertion following each advance of the needle upon reaching the ligamentum flavum could reduce the incidence of unintentional dural puncture

Methods:

Following IRB approval and informed consent, 1000 obstetric patients who were scheduled to receive epidural block were randomized to: Group I (n=500) patients who received lumbar epidural block with LOR to air technique without stylet reinsertion and Group II (n=500) patients who had the stylet reinserted upon reaching the ligamentum flavum each time the needle advanced 1-2 mm into the epidural space. When unintentional dural puncture was noticed, the epidural catheter was inserted 2-3 cm intrathecally for continuous spinal block.

Results:

Groups did not differ in age, weight, height, parity, previous history of neuraxial block, or distance of epidural space from the skin. 12/500 (2.4%) pts in group I had unintentional dural puncture compared with 2/500 (0.4%) pts in group II ($p < 0.01$, Fisher's exact test). LOR to air technique was achieved in 12 pts in group II following the last stylet insertion before further advancing the needle. 9 of 12 pts in group I, and 2 of 2 pts in group II with dural puncture had a history of previous epidural block.

Discussion:

This simple technique of reinserting the stylet helped reduce the incidence of accidental dural puncture. The dura may still be punctured, possibly due to its adhesion to the ligamentum flavum following a previous neuraxial block.

Conclusion:

We speculate that a blood clot and/or a flap of pierced ligament may occlude the lumen of the needle used for epidural analgesia, preventing loss-of-resistance to air injections despite having reached the epidural space. In this study we determined that stylet reinsertion following each advance of the needle upon reaching the ligamentum flavum could reduce the incidence of unintentional dural puncture.

TAAP – Thoracoabdominal Aortic Pseudoaneurysm

Rohan R. Shah[1] BA, Anthony Guglin[1] BA, Mohamed Bouhara[1] MD, Raymond Malapero[1] MD, MPH

[1] Department of Anesthesiology and Perioperative Medicine, Rutgers New Jersey Medical School, Newark, NJ, USA

Presenter: Rohan R. Shah, rs1520@njms.rutgers.edu
Anthony Guglin, ag1639@njms.rutgers.edu
Raymond Malapero, malaperj@njms.rutgers.edu

Abstract

Introduction: Thoracic aortic aneurysms have an incidence rate of 5-10 cases per 100,000 person-years and are usually found incidentally when patients undergo chest imaging (1, 2). Thoracic aortic aneurysm patients require multi-specialty care (2). Infected aortic aneurysms can require an even more challenging treatment plan. We present a case of a patient who presented to the hospital after a fall and was found to have a thoracic aortic aneurysm and thoracic vertebral osteomyelitis. Patient had a challenging intraoperative course that required invasive monitoring, complex anesthetic management, and TEE guidance.

Case: A 77-year-old with PMH of HTN and peripheral neuropathy presented to the ER with a head laceration following a fall. Trauma CT scan revealed a thoracoabdominal aortic pseudoaneurysm (TAAP) at the T12-L1 level as well as erosive development at the T12/L1 disc space. The patient underwent surgery to close the head laceration and a week later, underwent spinal surgery that included a posterior arthrodesis at the T10-T11, T11-T12, T12-L1, and L1-L2 levels. Patient was scheduled for a combined vascular, thoracic, and spinal surgery to occur 3 days later.

Intraoperative notes: Intravenous induction was completed with Fentanyl, Lidocaine, Propofol, and Rocuronium. After induction, an arterial line was placed along with two right IJ cordis central lines. The patient received a double lumen endotracheal tube for left lung isolation which allowed for a left thoracotomy approach. Isoflurane was used for anesthetic maintenance. For 56 minutes, the patient was on cardio-pulmonary bypass (CPB) to perfuse the lower body while the surgeon used infrarenal and suprarenal aortic cross clamps to provide a bloodless field during TAAP repair. A TEE was used to managed blood volume distribution and hemodynamics.

Following the retroperitoneal repair of the infected pseudoaneurysm with a cadaveric homograft aortic patch, the patient underwent a thoracolumbar corpectomy and fusion to treat severe osteomyelitis. During the corpectomy, to accommodate neurological monitoring, the patient was converted to TIVA (total intravenous anesthesia) and maintained with remifentanil and Propofol while receiving norepinephrine for hemodynamic support.

Postoperative notes: Patient was transferred to the SICU and extubated with normal neurologic examination. While in SICU, the patient developed new-onset atrial fibrillation subsequently treated with amiodarone. Post-operative course was complicated by ICU delirium and acute kidney injury.

Discussion: This is a unique case requiring vascular, cardiothoracic, and orthopedic surgical expertise. Thus, anesthetic management required large central venous access, arterial access, and TEE monitoring. CPB allowed for perfusion to sites distal to the clamped areas while TEE was utilized to balance volume distribution with CPB proximal and distal to clamp sites. Neuromuscular blockade reversal and TIVA were critical for neuromonitoring. Overall, anesthetic management was involved but successful in this complex, multi-specialty thoracic aortic repair.

References:

1. Atul Mathur, Varun Mohan, Deepak Ameta, Bhardwaj Gaurav and Pradeep Haranahalli. “Aortic aneurysm.” J Transl Int Med. 2016 Apr 1; 4(1): 35–41.

2. Kuzmik GA, Sang AX, Elefteriades JA. “Natural history of thoracic aortic aneurysms.” J Vasc Surg. 2012;56:565

Title:
Anesthesia Management of Dental Rehabilitation in a Pediatric Patient with Angelman Syndrome

Authors: Eberechi Uche MS-4 (ecu7@njms.rutgers.edu) , Andrew Hong CA-1 (ayh26@njms.rutgers.edu) , Glen Atlas (atlasgm@njms.rutgers.edu)
Presenters: Eberechi Uche MS-4 (ecu7@njms.rutgers.edu) , Andrew Hong CA-1 (ayh26@njms.rutgers.edu)

Introduction:
The objective of this case report is to examine the successful perioperative anesthetic management for dental rehabilitation of a pediatric patient with Angelman Syndrome. Patients with Angelman Syndrome are characterized by their partial deficit of chromosome 15, which contain the subunits of the γ-aminobutyric acid (GABA)-A receptor. Studies have suggested that patients with Angelman Syndrome have relative deficiency of β3 subunits that make up their GABA-A receptors.[1] Because the majority of currently used anesthetics affect the CNS through the GABA system, the implications on anesthetic management can be profound. This patient's epilepsy, significant dominance of the vagal tone, craniofacial abnormalities and peripheral muscular atrophy had to be taken into consideration when administering anesthesia.

Methods:
A 15-year-old male with Angelman Syndrome and medical history of global developmental delay and epilepsy underwent dental rehabilitation requiring general anesthesia. Because the patient was hyperactive preoperatively, before entering the operating room the patient was sedated successfully sedated with ketamine and glycopyrrolate. A peripheral intravenous line was then able to be placed. Inhalation induction was performed with isoflurane and nitrous oxide. The endotracheal tube was placed intranasally. Anesthesia was maintained with nitrous oxide and isoflurane. Intraoperative hypotension required titration of multiple doses of phenylephrine. Additionally, the Larson Maneuver was performed successfully after extubating due to the patient experiencing laryngospasms. The patient tolerated the procedure well and his mother reported he had returned to his baseline mental function in the post anesthesia care unit and was subsequently able to go home the same night.

Conclusions:

Patients with Angelman syndrome appear to have a relative deficiency of β3 subunits to compose their GABA-A receptors. Because the majority of currently used anesthetics affect the CNS through the GABA system, it has been suggested that patients with Angelman syndrome are at increased risk for complications both during and following the administration of anesthesia due to modified receptor kinetics and pharmacodynamic unpredictability.[2] We

present a patient who was able to receive general anesthesia with inhaled anesthetics, and with few complications.

---

[1] Bevinetto CM, Kaye AD. Perioperative considerations in the patient with Angelman syndrome. J Clin Anesth. 2014 Feb;26(1):75-9. doi: 10.1016/j.jclinane.2013.07.015. Epub 2014 Jan 17. PMID: 24440034.

[2] Landsman IS, Mitzel HM, Peters SU, Bichell TJ. Are children with Angelman syndrome at high risk for anesthetic complications? Paediatr Anaesth. 2012 Mar;22(3):263-7. doi: 10.1111/j.1460-9592.2011.03661.x. Epub 2011 Aug 1. PMID: 21801274.

A Simple Low-Flow Nasal Mask-Face Tent Maintained Spontaneous Nasal CPAP Ventilation/Oxygenation and Reduced Aerosol/Droplet Spread in an Obese OSA Patient with Jarcho-Levin Syndrome and an Extreme Difficult Airway during Colonoscopy under MAC

Karina Braslavskaya, MD, Akshay Goyal MD, Jessica Mahajan, MD , Antonio Chiricolo, MD and James Tse, PhD, MD
Department of Anesthesiology and Perioperative Medicine
Rutgers Robert Wood Johnson Medical School, New Brunswick, NJ

*e*Poster Presentation at the Vertual NJSSA 62nd Spring Annual Meeting, Feb 12, 2022

RUTGERS
THE STATE UNIVERSITY OF NEW JERSEY

Background: Patients under monitored anesthesia care (MAC) often receive IV sedation and oxygen via a nasal cannula. Over-sedation and/or airway obstruction may result in severe desaturation, especially in obese patients with obstructive sleep apnea (OSA). A simple modified pediatric facemask has been shown to provide nasal CPAP ventilation and improve oxygenation in deeply sedated OSA patients (Fig. 1).[1-6]

Amid the COVID-19 pandemic, a nasal mask-face tent provided continuous oxygenation and reduced aerosol/droplet spread during RSI and intubation/extubation in COVID-19 positive patient.[7] It avoided severe desaturation and reduced aerosol/droplet spread during difficult intubation/extubation in a morbidly obese patient (Fig. 2).[8]

We used this simple combined nasal mask-face tent to provide nasal CPAP oxygenation in a patient with Jarcho-Levin Syndrome (JLS) (Fig. 3) and extremely difficult airway undergoing outpatient colonoscopy.

Case Description: A COVID-negative 21 year-old male, 4'10'', 72.3 kg, BMI 33.2 kg/m^2, with JLS, Von Willebrand disease, OSA noncompliant with CPAP, asthma, respiratory insufficiency, restrictive lung disease, mild aortic insufficiency, sinus tachycardia and diverticulitis presented for out-patient pre-operative colonoscopy.

The patient had a Class IV airway and typical JLS features of shortened thorax, severe scoliosis and kyphosis, and an extreme short neck with limited range of motion, wide nasal bridge and protuberant abdomen. He was shown a modified infant facemask and gave his consent for its use, taking photographs and presenting a case report.

The modified infant facemask with a fully inflated air-cushion was secured over his nose and connected to the anesthesia machine via a long breathing circuit delivering 7-10 cm H_2O CPAP with 4L O_2/min (Fig. 4).

Following his SpO_2 improved from 97% to 100%, moderate sedation was titrated with 100 mg lidocaine and 50 mg propofol boluses (x3) and maintained on propofol infusion (150-400 mcg/kg/min). His mouth was covered with a clear face tent and a suction catheter was placed under the face tent to reduce aerosol/droplet spread (Fig. 5).

He maintained spontaneous ventilation without any airway manipulation and 97-100% SpO_2 throughout the difficult procedure (Fig. 6). He required a relatively high dosage of propofol (a total of 650 mg) for the 30-min procedure. He recovered quickly without complication and maintained 100% SpO_2 with nasal cannula O_2 (4L/min) and a face tent.[1] He was alert and elated prior to transport to the PACU. He was discharged home without any complications.

Fig. 1. A modified infant face mask secured over the nose and connected to an adult breathing circuit .

Fig. 2. . A large, clean, clear plastic sheet is taped to the lower part of the mask.

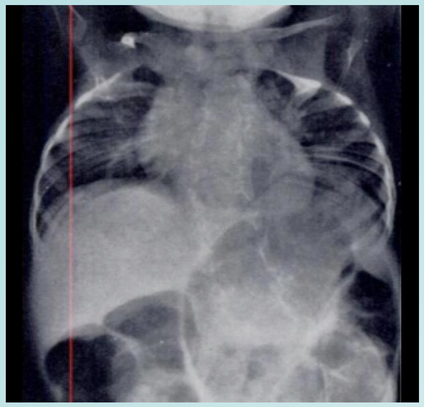

Fig. 3. JLS features: Fanlike configuration of the ribs, with extensive posterior fusion, along with multiple vertebral segmentation defects.

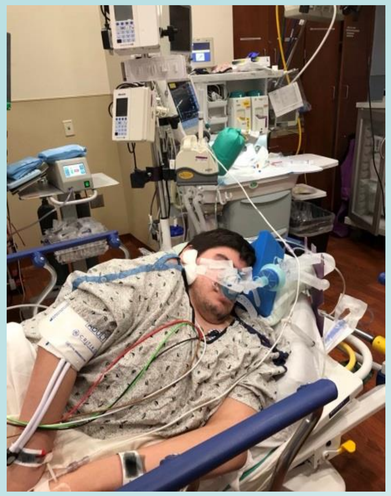

Fig. 4. A nasal mask maintained spontaneous CPAP ventilation/oxygenation.

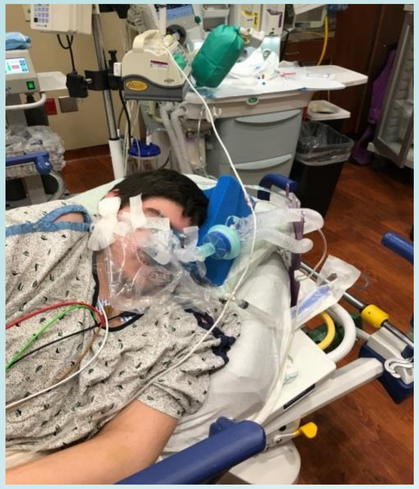

Fig. 5. A face tent covered the mouth to reduce aerosol/droplet spread.

Fig. 6. His SpO_2 was maintained at 97-100% throughout the procedure.

Discussion: This simple combined nasal mask-face tent maintained spontaneous CPAP ventilation/oxygenation in an obese patient with Jarcho-Levin Syndrome, respiratory insufficiency and an extreme difficult airway during outpatient colonoscopy. It also reduced aerosol/droplet spread during the procedure.

Amid the ongoing COVID-19 pandemic, it may improve patient safety and provide additional provider protection at a low cost.

References: 1. www.TSEmask.com; 2. SAMBA 28th AM, MCC, 2013; 3. SASM MC's, 2013; 4. ASA AM: MC536 & 1100, 2013; 5. 67th PGA: MCC 7094, 7115, 7120, 7129, 7189, 7199 & 7203, 2013; 6. SAM AM: MCC's, 2014; 7. ASA AM: MC1280, 2020; 8. 74th PGA: MCC201, 2020

A Simple Low-Flow Nasal Mask-Face Tent Provided Pre-/Apneic Oxygenation and Reduced Aerosol/Droplet Spread In a COVID-19 Positive Patient during RSI and Intubation/Extubation

[1]Brittany Ahuja, MD, [1]Scott Mellender, MD, [2]Tejas U. Shah, MD and [1]James Tse, PhD, MD

[1]Department of Anesthesiology and Perioperative Medicine,
Rutgers Robert Wood Johnson Medical School, New Brunswick, NJ
[2]Dept of Neuroscience, University of Kentucky - King's Daughter's Medical Center, Ashland, KY

ePoster Presentation at the Virtual NJSSA 62nd Annual Spring Meeting, Feb. 12, 2022

RUTGERS
THE STATE UNIVERSITY OF NEW JERSEY

Background: A plastic sheet has been used to convert an ineffective nasal cannula to an effective face tent (FT) which delivers >0.6 FiO_2 with 4L O_2/min to prevent desaturation during MAC.[1-2]

A simple nasal mask assembly using a modified pediatric face mask has been shown to provide nasal CPAP to maintain spontaneous ventilation and improve oxygenation in deeply sedated obese OSA patients and nasal oxygenation to patients with difficult airway during GA induction (Fig. 1-3).[2-6]

In March 2020 amid the COVID-19 pandemic, we combined these two simple techniques as a universal precaution device in addition to recommended PPE (Fig. 4-11). We described the use of the combined nasal mask-face tent in a COVID-19 positive patient during GA induction , intubation and extubation.

Case Description: A 20-year-old COVID-19 positive male, s/p gun-shot wound to RLQ, s/p exploratory laparotomy/right nephrectomy/cholecystectomy, presented for emergency re-exploration in a negative-pressure OR.

A modified infant facemask was secured over his nose with elastic head-straps and connected to the anesthesia circuit/machine with 4L O_2/min. His mouth was covered with a clear plastic sheet (face tent) to reduce aerosol/droplet spread. (Fig. 5)

Following pre-oxygenation, RSI was induced with lidocaine, propofol and succinylcholine. To avoid generating aerosol, assisted ventilation was not done (Fig. 6). Video-laryngoscopy (VL) assisted intubation was performed under the face-tent while the nasal mask delivered apneic oxygenation (Fig. 7-8). His SpO_2 was maintained at 100% during induction and intubation. He tolerated the procedure well.

Prior to extubation, the nasal mask was secured over his nose and a clean plastic sheet covered his mouth and ETT (Fig. 9). He was extubated deep and smoothly under the face tent. The breathing circuit was immediately connected the nasal mask to provide nasal CPAP (2 cm H_2O) with 4L O_2/min (Fig. 10). He maintained spontaneous nasal ventilation and 100% SpO_2 (Fig. 11). His mouth was covered with the face tent to reduce droplet/aerosol spread. He was transported to the COVID ICU without complications.

Discussion: This simple combined modified nasal mask-face tent provided nasal pre-oxygenation/apneic oxygenation and reduced droplet/ aerosol spread during RSI, intubation and extubation in a COVID-19 positive patient.

It may improve patient safety and provide additional provider protection besides PPE and should be routinely used as a universal precaution amid the ongoing COVID-19 pandemic.

References: 1. Anesthesiology 102: 484, 2005; 2. www.TseMask.com; 3. SAMBA 28th AM, 2013; 4. NYSSA 67th PGA: MCC-7189, MCC-7120, 2013; 5. IARS AM: MCC668, 2014; 6. SAM AM, MCC, 2014

Fig. 1. An infant mask was secured over the nose with elastic head-straps and connected to a breathing circuit.

Fig. 2. To modify a infant mask by squeezing it for 1-2 mins

Fig. 3. Infant mask (size #2) (left) and the modified infant mask (right).

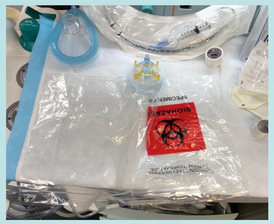

Fig. 4. A large clean clear plastic sheet is taped to the lower part of the mask.

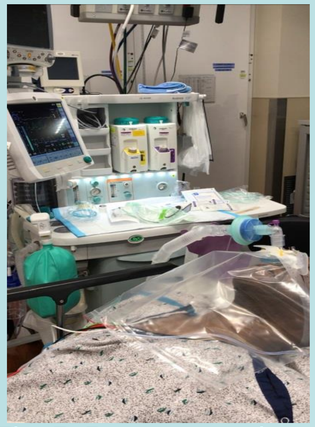

Fig. 5. Pre-oxygenation with the combined nasal mask-face tent (4LO_2/min).

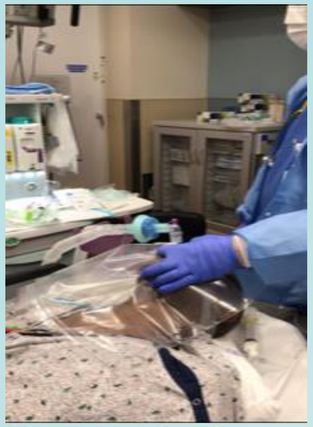

Fig. 6. Holding the nasal mask & closing the mouth following RSI.

Fig. 7. A disposable video-laryngoscope can be inserted under the face tent.

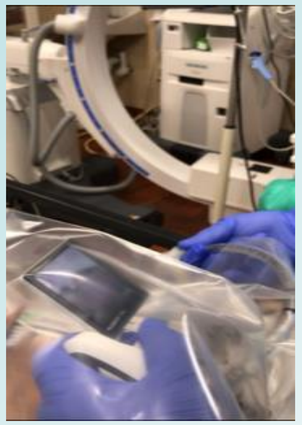

Fig. 8. Inserting ETT from right side of the mouth under the face tent

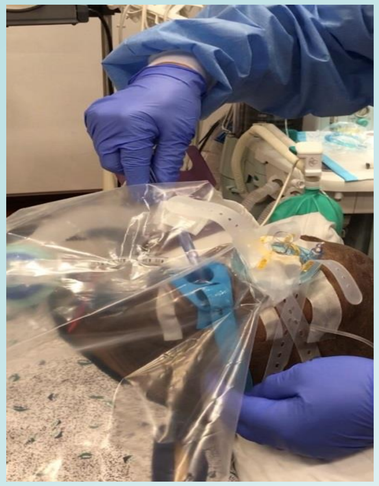

Fig. 9. Prior to extubation, the nasal mask and another clean plastic sheet can be secured over the nose and covered the mouth and ETT.

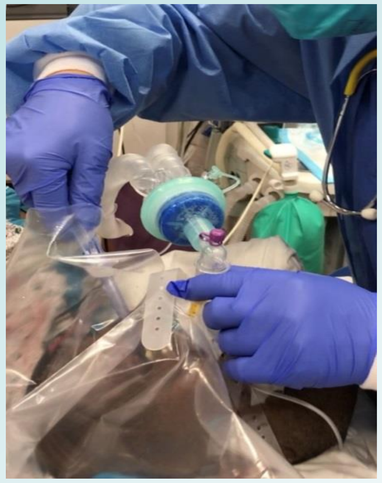

Fig. 10. Immediately post-extubation, check nasal ventilation/oxygenation with the mouth closed and perform oral suctioning under the face tent as needed.

Fig.11. Post-extubation, the patient maintained spontaneous nasal ventilation and oxygenation with nasal CPAP (2 cm H_2O).

A Simple Low-Flow Nasal Mask-Face Tent and Oral Suctioning Provided Continuous Oxygenation and Reduced Aerosol/Droplet Spread in an Obese OSA Patient with Previous Severe COVID-19 Pneumonia during POEM

Andrew Milanesi , MD, Kaavya Mahajan, BA and James Tse, PhD, MD
Department of Anesthesiology and Perioperative Medicine
Rutgers Robert Wood Johnson Medical School, New Brunswick, NJ
*e*Poster Presentation at the Virtual NJSSA 62nd Annual Spring Meeting, Feb. 12, 2022

RUTGERS
THE STATE UNIVERSITY OF NEW JERSEY

Background: Minimization of aerosol/droplet spread, with the goal of providing maximal oxygenation is a primary concern for patients undergoing general anesthesia amid the COVID-19 pandemic. A pediatric facemask has been shown to provide nasal CPAP ventilation/oxygenation in obese OSA patients (Fig. 1).[1-2]

A novel combined nasal mask-face tent provided continuous oxygenation and reduced aerosol/droplet spread in a COVID-19 positive patient.[3] It also avoided severe desaturation and reduced aerosol/droplet spread during difficult intubation/extubation in a morbidly obese patient (Fig. 2).[4]

We used this simple technique to provide continuous oxygenation and lower aerosol/droplet spread in an obese OSA patient recovered from severe COVID-19 pneumonia undergoing peroral endoscopic myotomy (POEM).

Case Report: A 60-year-old obese male with OSA, atrial-fibrillation, cardiomyopathy, severe COPD on home O_2, previous severe COVID-19 pneumonia s/p convalescent plasma therapy, and achalasia presented for POEM.

An infant facemask with fully inflated air cushion was secured over his nose with elastic head-straps and connected to the anesthesia machine via a long breathing circuit. His mouth was covered with a clear plastic sheet (face-tent) to reduce aerosol/droplet spread.

Following nasal CPAP pre-oxygenation with 4L O_2/min, RSI with cricoid pressure was induced with lidocaine, etomidate, propofol and succinylcholine. Video-laryngoscopy-assisted intubation was performed under the face-tent while the nasal mask delivered apneic oxygenation (Fig. 3). His SpO_2 was maintained at 100% throughout induction and intubation.

During the procedure, he developed tension pneumoperitoneum with insufflated CO_2 which was reduced with 14G angiocatheter x3 by the endoscopist. Upon conclusion of POEM, the nasal mask-face tent was re-secured over his nose and covered his mouth.

After 5 cc of 2% lidocaine spray was delivered through the endotracheal tube (ETT) to reduce coughing, ETT was suctioned clear of secretion under the face tent. The patient resumed spontaneous respiration and his oropharynx was suctioned under the face tent prior to extubation.

Post-extubation, he became agitated and required additional propofol, fentanyl and dexmedetomidine and three providers to restrain him in order to maintain spontaneous nasal CPAP ventilation/oxygenation and allow frequent oral suctioning for >20 mins (Fig. 4)). Subsequently, the patient received nasal cannula O_2 with a face tent in PACU and recovered without any complications.

Fig. 1. A modified infant face mask secured over the nose and connected to an adult breathing circuit.

Fig. 2. . A large clean clear plastic sheet is taped to the lower part of the mask.

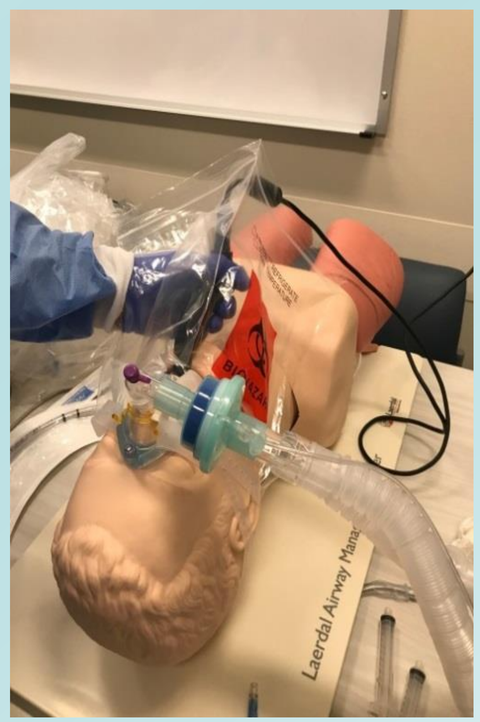

Fig. 3. Mannequin demonstrating video-laryngoscopy-assisted intubation performed under the face-tent while the nasal mask delivering apnoeic oxygenation.
.

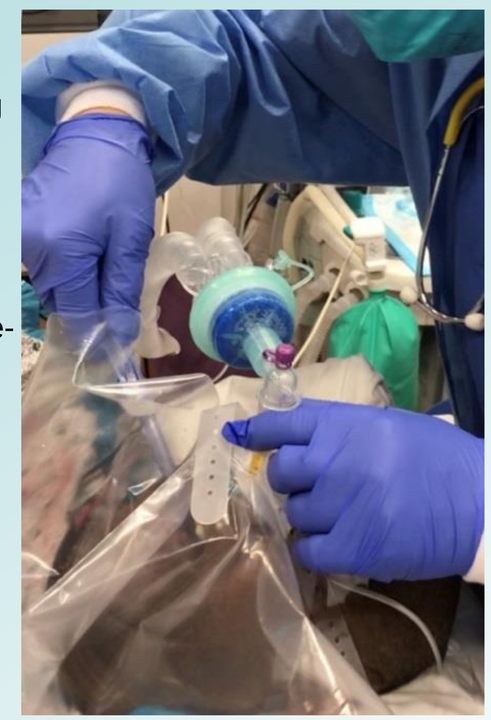

Fig. 4. Post-extubation, the nasal mask-face tent maintained spontaneous CPAP oxygenation and minimized aerosol/droplet spread during frequent oral suctioning.

Discussion: This simple nasal mask-face tent provided continuous oxygenation during RSI and intubation in an obese OSA patient with previous severe COVID-19 pneumonia undergoing POEM. It maintained spontaneous nasal CPAP ventilation and oxygenation post-extubation in the patient with emergent delirium. Combining with oral suctioning under the face tent, it reduced aerosol/droplet spread.

Amid the ongoing COVID-19 pandemic, it may optimize patient safety and provide additional provider protection at no extra cost.

References: 1. www.TSEmask.com; 2. SAMBA 28th AM, MCC, 2013; 3. ASA AM:MC1280, 2020; 4. NYSSA 74th PGA:MCC201, 2020

Title:
Two Valves are Better than None: Hepatic congestion and heart failure secondary to severe mitral regurgitation and missing tricuspid leaflets

Authors:

1. Jasvir K. Kaila, DO
2. Raymond Malapero, MD, MPH

Introduction:

The complex blood supply of the liver lends itself to have a unique physiological relationship with the heart. Hepatic dysfunction secondary to cardiac disease is known as cardiohepatic syndrome. There are multiple classifications and causes of this disease (1). One common etiology is elevated right heart pressures that translate to hepatic congestion. The following case demonstrates the anesthesia challenges in a patient with hepatic congestion secondary to tricuspid valve removal in the setting of endocarditis now requiring mitral valve and tricuspid valve replacement. This case is further complicated by the patient's multiple comorbidities and history of mitral valve replacement secondary to infective endocarditis.

Case Presentation:

A 41-year-old male with a PMH of SVT s/p ablation, Hepatitis C secondary to IV drug use, alcohol abuse, prior tricuspid valve leaflet removal and mitral valve replacement secondary to endocarditis presented with hepatic congestion and dyspnea at rest. His TTE demonstrated severe MR and wide-open TR now requiring mitral valve and tricuspid valve replacement. It was found that during his prior endocarditis episode, the mitral valve was replaced, and the tricuspid valve had the anterior and septal leaflets removed. After central line placement in the ICU, the patient was noted to have elevated PA pressures that required a milrinone infusion. He underwent induction with midazolam, ketamine, propofol, fentanyl, and rocuronium. Milrinone was left infusing. Both valves were replaced during an uneventful pump run. After coming off the pump, the patient had a significant pressor demand that required the initiation of dobutamine, epinephrine, milrinone, vasopressin, and norepinephrine. The patient was stabilized and did not require IABP. He was extubated the following morning and on POD 1 he was weaned off all the pressors except milrinone. On POD 2, the patient was weaned off milrinone, as well. His pre-op AST and ALT of 140 and 70, respectively, decreased post-operatively to 40 and 50 with a continued downward progression. Additionally, he was neurologically intact and satisfied with care.

Discussion:

The mainstay treatment of infective endocarditis is antibiotic therapy with surgery indicated for optimal therapy in patients with a complicated course of IE (2). Hepatic congestion in the setting of mitral valve endocarditis has been shown to improve with TVR and MVR (3). This case demonstrates the sequelae of tricuspid valve removal including hepatic congestion leading to

liver failure with superimposed severe MR in the setting of a damaged bioprosthetic mitral valve. These patients are prone to perioperative hemodynamic instability and coagulopathy due to the effects of cardiohepatic syndrome.

Conclusion:

Treatment of hepatic congestion in cardiohepatic syndrome is to treat the underlying cardiac disease and improve cardiac function. Replacement of the TV and MV in patients with hepatic congestion secondary to valvular disease has been shown to improve liver function.

References:

1. Poelzl, Gerhard, and Johann Auer. "Cardiohepatic Syndrome." Current Heart Failure Reports, vol. 12, no. 1, 2014, pp. 68–78., doi:10.1007/s11897-014-0238-0.
2. Baddour, Larry M., et al. "Infective Endocarditis in Adults: Diagnosis, Antimicrobial Therapy, and Management of Complications." Circulation, vol. 132, no. 15, 2015, pp. 1435–1486., doi:10.1161/cir.0000000000000296.
3. Lin, Peter M., et al. "Acute Liver Failure with Extreme Hyperbilirubinemia Secondary to Endocarditis-Related Severe Mitral and Tricuspid Regurgitation: A Challenge and an Opportunity for Surgeons." Journal of Thoracic Disease, vol. 10, no. 2, 2018, pp. 1067–1071., doi:10.21037/jtd.2018.01.138.

Title: Rate of Greater than National Average UH CLABSI

Kwame Awuku, MD, Daniel Denis, DO, Sofia Gilels, MD, Kruti Parikh, MD,
Jennifer Umeugo, MD, Victoria Whitehead, MD, Jean Eloy, MD
Department of Anesthesiology Rutgers – New Jersey Medical School, Newark, New Jersey

Contact Information:
Sofia Gilels, MD
Anesthesiology Resident Physician, PGY4
Rutgers New Jersey Medical School
Newark, NJ

Project:
Rate of Greater than national average UH CLABSI

Objective:
Investigate University Hospital line placement statistics for January 1, 2019 - December 31, 2020 including site of catheter placement, pathogens involved, and locations of placement (ICU vs PACU vs Trauma Bay vs Floors)

Background:
Central line-associated bloodstream infections (CLABSIs) result in thousands of deaths each year and billions of dollars in added costs to the U.S. healthcare system [1]. A central line, or central venous catheter (CVC), is placed in a major vein in the neck, chest, or groin in most commonly a critically ill patient, to give medication or fluids or to collect blood specimens' medical tests, and can remain in place for days to months. There are several complications associated with CVCs, including pulmonary, vascular, cardiac, device dysfunction, infection, and placement complications.

Infection is a serious adverse outcome associated with CVC that can lead to sepsis, shock, and death. An estimated 30,100 CLABSIs occur in intensive care units and wards of U.S. acute care facilities each year [1]. The Centers for Disease Control and Prevention (CDC) estimates the additional cost per infection to be on average approximately $16,550 [2]. Mortality related to central line infection can occur in up to 25% of cases [2]. Catheter infection sources are most commonly from contamination from skin flora, and less commonly from contamination from infused substance, or from hematogenous spread from an unrelated site [2]. The most important extrinsic risk factors associated with the development of CLABSIs include:

- duration of catheterization (although there is no indication for routine line changing based on number of catheter days),
- conditions of insertion,
- catheter-site care, and
- skill of the catheter inserter
- site of catheter placement
- nontunneled compared to tunneled insertion

- bare compared with antibiotic- impregnated catheter [3]

CLASBIs can be prevented by adhering to the recommended hospital policies on CVC insertion and care. CDC recommended practices regarding CVC placement include:

- performing proper hand hygiene
- applying appropriate skin antiseptic
- ensuring that the skin prep agent has completely dried before inserting the central line
- using all five maximal sterile barrier precautions: sterile gloves, sterile gown, cap, mask and large sterile drape

CDC recommended practices for CVC maintenance and care include:

- washing hands with soap and water or an alcohol-based hand rub before and after touching the line
- removing a central line as soon as it is no longer needed [1]

The goal of our project is to investigate these extrinsic risk factors that are associated with the development of CLABSIs, and determine which factors play a significant role in the elevated rate of CLABSI at University Hospital.

Methods:
Used the information available including the site of catheter placement, pathogens involved, and locations of placement (ICU vs PACU vs Trauma Bay Vs Floors)

Results:

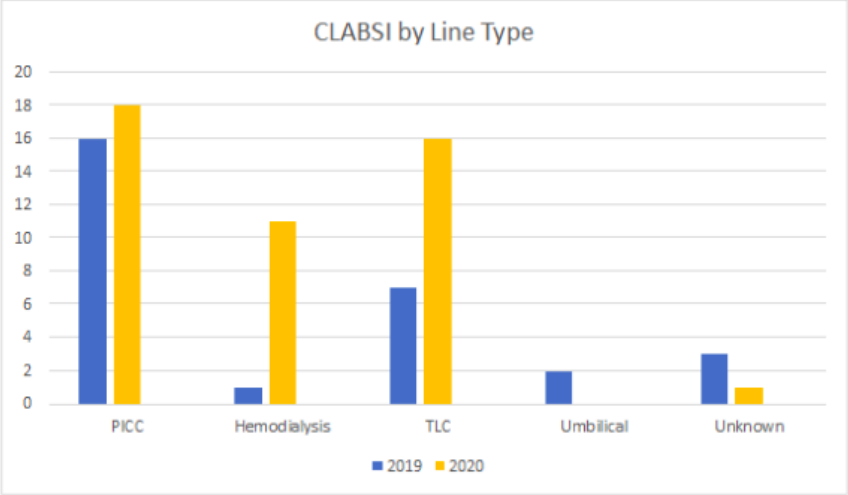

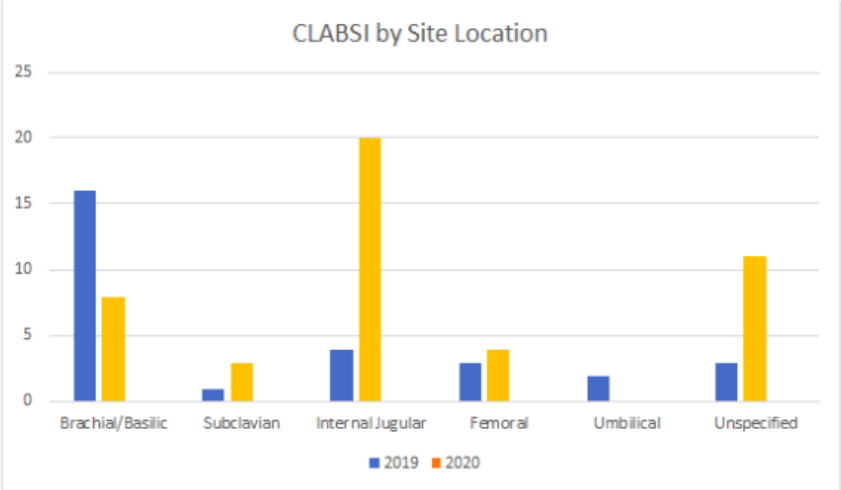

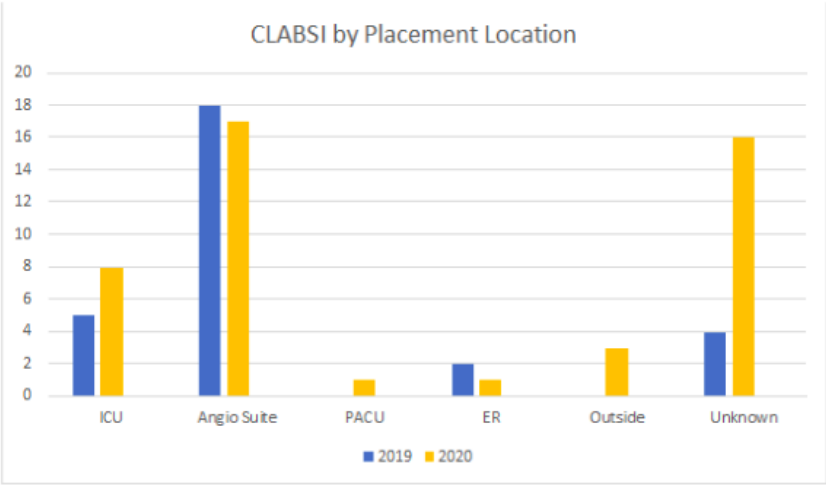

CLABSI Data from 2019 & 2020

	2019	2020
Number of Infections	29	46
Number of Line Days	14,763	18,867
Number of Patient Days	80,778	81,074
Infection Rate	1.96	2.44
Utilization	0.18	0.23
Number of Expected (NHSN)	17	9
SIR	1.65	1.3

Discussion:

At University Hospital 2020 saw more line associated infections (46) compared to 2019 (29), as well as a higher infection rate per 1,000 line days (2.44 vs. 1.96). When comparing the location of the line placement as well as the type of line, the majority of infections from both 2019 and

2020 came from PICC (peripherally inserted central catheters) which are almost always placed in the Interventional Radiology Suite and typically in one of the upper extremity veins. Interestingly, there were no CLABSIs documented to central lines placed in the OR, and very few to those placed in the PACU or ED. With the provisioning of EPIC EMR based anesthesia records, the documenting of type, location, and provider for all central lines placed by the anesthesiology department in the operating room is now mandatory and easy to analyze.

References:

1. Central Line-associated Bloodstream Infections: Resources for Patients and Healthcare Providers. Centers for Disease Control and Prevention. https://www.cdc.gov/hai/bsi/clabsi-resources.html. Published February 7, 2011. Accessed March 23, 2020.
2. Kornbau C, Lee KC, Hughes GD, Firstenberg MS. Central line complications. *Int J Crit Illn Inj Sci*. 2015;5(3):170–178. doi:10.4103/2229-5151.164940
3. Gaynes R, Jacob JT. Intravascular catheter-related infection: Epidemiology, pathogenesis, and microbiology. UpToDate. https://www.uptodate.com/contents/intravascular-catheter-related-infection-epidemiology-pathogenesis-and-microbiology?csi=3ca2b1c6-e2e5-402e-a13d-ca503e961024&source=contentShare. Published March 28, 2019. Accessed March 23, 2020.

Title: FLUOROSCOPY GUIDED SPLANCHNIC NERVE BLOCK AS AN OPTIMAL ALTERNATIVE IN MANAGEMENT OF INTRACTABLE PAIN DUE TO CHRONIC PANCREATITIS

Authors
Kwame Awuku MD[1], Steven Char MD[1], Akwasi Amponsah MD[1], Mina Gaballa DO[1], Jean Eloy MD[1], Andrew Kaufman MD[1]
[1]*Rutgers New Jersey Medical School, Newark NJ*

Contact Information:
Kwame Awuku, MD
Resident Physician, PGY3
Anesthesiology Department
Rutgers New Jersey Medical School Newark, NJ
kawuku@njms.rutgers.edu

Introduction

The pain associated with chronic pancreatitis (CP) can be debilitating, often leading to excessive use of narcotic analgesics. Studies have shown that eighty-five percent of patients with chronic pancreatitis will develop pain at some time during their disease [1]. Abdominal pain is the predominant symptom, severely impairing the quality of life of those affected. Patients with CP frequently complain of epigastric pain that radiates to the back. Since these abdominal symptoms lack a consistent nature, its management strategy is difficult and presents a major challenge for clinicians. Furthermore, it frequently presents chronically with the mainstay therapy with medications such as NSAIDs and narcotics. However, the continued use of these medications often leads to unpleasant side effects that may worsen symptoms like those caused by CP such as nausea and vomiting, constipation, and potentially fatal complications in patients with liver and renal insufficiency. The pancreas has an abundant nerve supply with sympathetic, parasympathetic, and sensory nerves that permeate it to participate in normal activities. Acute inflammation in CP from chronic inflammatory cells invades and damages nerves leading to activation of afferent nerves producing severe pain [2]. The splanchnic nerve block is a technique aimed at interrupting the neural conduction since it transmits most of the nociceptive information causing abdominal pain [3]. Previous studies focused on this technique being classically performed for patients with pain associated with intra-abdominal cancer. However, in recent years the technique has expanded to include a variety of indications such as pain from CP. We describe a case report for management of intractable abdominal pain with fluoroscopic guided bilateral splanchnic nerve blocks in a young female with CP and status post distal pancreatectomy.

Materials/Methods

Bilateral Splanchnic nerve blocks were performed under fluoroscopic visualization to confirm needle and injectate localization. The T12 vertebral body was identified, and a 25-gauge ⅝ inch

needle was used to inject 1% lidocaine to anesthetize the skin. A 22-gauge 8.0-inch Chiba needle was then incrementally advanced towards the vertebral bodies in an oblique orientation. Upon bony contact, the needle was advanced in a lateral view to the anterior/lateral/inferior one-third portion of the T12 vertebral body. After negative aspiration, 0.5ml of contrast showed adequate bilateral anterolateral spread along the T12 vertebral body. A total of 19ml of 0.25% bupivacaine and 1ml of 80mg methylprednisolone was injected, 10ml on each side. There was no evidence of intravascular, intrathecal placement, and no paresthesia was noted. The patient tolerated the procedure well, with stable vital signs maintained throughout the procedure and two hours during observation. This case report is devoid of patient identifiable information and is exempt from IRB review requirements. Patient informed consent was obtained.

Results/Case Report

A 31-year-old female with significant medical history of alcohol-use disorder complicated by chronic pancreatitis, diabetes mellitus II, and status-post distal pancreatectomy, presented to the emergency room due to severe chronic abdominal pain associated with decreased oral intake. Patient described a severe upper abdominal pain that radiates to the back associated with constipation, nausea and vomiting. Physical examination showed abdominal tenderness to palpation in the epigastric region associated with guarding and hyperalgesia but no rebound tenderness or allodynia. CT scan of the abdomen and pelvis showed a beaded dilated appearance of the pancreatic duct with calcifications. During her hospital course, the patient was given IV fluids, pancreatic enzymes and multiple doses of opioid regimens including IV morphine and hydromorphone without improvement of pain. Pain service was consulted, and we performed bilateral splanchnic nerve blocks in the setting of failed conservative and surgical management.

Pre-injection pain visual analog scale (VAS) score was 9/10. Post-injection pain VAS score was 0/10 with 90% improvement in pain symptoms reported by the patient during 48 hours after the procedure. Opioid requirements were reduced and the patient. Upon discharge, the patient was counseled on potential benefits of performing radiofrequency ablation in the future.

Discussion

The complex pathogenesis of the painful disease state in chronic pancreatitis remains a challenge for clinicians and requires further research in order to guide treatment efforts. There have been numerous mechanisms about the source of the pain generation in this disease. Traditional theories focused on a mechanical cause of pain related to changes secondary to inflammation with evidence of increased ductal pressures [4]. This has led to management with surgical and decompression procedures when medical therapy has failed. However, a neural basis of pain can occur in CP and has become the focus of research in recent years [4].

Intrapancreatic nerve lesions are associated with upregulation of proinflammatory cytokines and have been reported to cause pancreatic neuropathy. Activation of glia and immune cells may lead to direct changes in the dorsal root ganglia of neurons innervating the pancreas resulting in visceral hyperalgesia seen in CP patients [4]. Furthermore, peripheral and central

sensitization results in increased pain signals to the spinal cord as well as sustained responsiveness of central pain transmitting neurons [4].

The presence of neural aberrance in CP makes the splanchnic nerve block an ideal target for treatment. It can lead to a reduction in narcotic usage in patients who have failed conservative and surgical therapy. The greater splanchnic nerve (GSN) is the largest of 3 paired sympathetic nerves (T5-T12) supplying the abdominal viscera and is clinically responsible for most cases of chronic upper abdominal pain. Visceral pain fibers arising from the pancreas travels with the celiac plexus to synapse in the celiac ganglia. This afferent pathway utilizes the same white communicating rami, ventral rami, and spinal nerves to arrive at the dorsal roots of the spinal cord [5]. The celiac plexus block can also be performed for management of visceral pain due to chronic pancreatitis. However, we chose the splanchnic nerve block because the nerves are contained in a narrow compartment, making them accessible for radiofrequency lesioning to achieve a more long-term relief [5]. Due to these potential benefits, our team performed a diagnostic bilateral splanchnic nerve block to provide analgesia for our patient. Our results showed that the procedure was an effective therapeutic approach with diagnostic potential for future consideration with radiofrequency lesioning.

References

1. Goulden MR. The pain of chronic pancreatitis: a persistent clinical challenge. *Br J Pain*. 2013;7(1):8-22. doi:10.1177/2049463713479230
2. Vera-Portocarrero L, Westlund KN. Role of neurogenic inflammation in pancreatitis and pancreatic pain. *Neurosignals*. 2005;14(4):158-165. doi:10.1159/000087654
3. Ahmed A, Arora D. Fluoroscopy-guided Neurolytic Splanchnic Nerve Block for Intractable Pain from Upper Abdominal Malignancies in Patients with Distorted Celiac Axis Anatomy: An Effective Alternative to Celiac Plexus Neurolysis - A Retrospective Study. *Indian J Palliat Care*. 2017;23(3):274-281. doi:10.4103/IJPC.IJPC_28_17
4. Demir IE, Tieftrunk E, Maak M, Friess H, Ceyhan GO. Pain mechanisms in chronic pancreatitis: of a master and his fire. *Langenbecks Arch Surg*. 2011;396(2):151-160. doi:10.1007/s00423-010-0731-1
5. Jeffrey D. Petersohn, 42 - Sympathetic Neural Blockade, Editor(s): Ted A. Lennard, Stevan Walkowski, Aneesh K. Singla, David G. Vivian, Pain Procedures in Clinical Practice (Third Edition), Hanley & Belfus, 2011, Pages 507-519, ISBN 9781416037798, https://doi.org/10.1016/B978-1-4160-3779-8.10042-9. (https://www.sciencedirect.com/science/article/pii/B9781416037798100429)

Title: Role of Repeat Mitral Valve Reclipping After Torn Mitral Leaflet in Severe MR

Author: Linda Laham (lindalaham11@gmail.com) (908-458-3882), Raymond Malapero (malaperj@njms.rutgers.edu)
Presenter: Linda Laham

Introduction:
Mitral regurgitation is the leading heart valve disease associated with high morbidity and mortality if gone untreated. Mitral valve clip repair has provided a transcatheter approach for many untreated patients with severe MR or at high surgical risk [1]. Transcatheter approach is now recommended as an addition to surgical repair if anatomy is appropriate. However, there is always the potential for complications, including a risk of leaflet rupture. The decision to proceed with another mitral clip versus surgical repair is dependent on severity of the regurgitation and patient stability. This report presents a case in which severe MR s/p torn mitral clip leaflet was successfully managed with an additional mitral clip versus the alternative surgical intervention.

Case Report:
This is a 81 year old male with PMH of prostate CA s/p radiation seeds, HTN, HLD, total right carotid occlusion that presented with a history of severe MR. Decision was made by the cardiothoracic and cardiology team to place a mitral clip in order to decrease severity. The mitral clip was placed with a subsequent decrease in his MR to mild. Patient presented back six months later with new chief complaint of new onset shortness of breath. Repeat TTE demonstrated severe MR with a torn mitral leaflet. Patient was subsequently brought back for an elective mitral clip placement at the area of the torn leaflet. Anesthetic plan was to induce with propofol, fentanyl, and rocuronium and maintained on sevoflurane. The new mitral clip was placed at the area of the torn leaflet with decrease in the severity of the MR to mild. Patient met extubation criteria with normal neurological exam and extubated in the operating room. Following monitoring and diuresis, the patient was discharged on POD3 for regular cardiology follow-up.

Discussion:
Placement of mitral clips is the leading transcatheter technique to treat MR and is relatively safer than mitral surgery with lower adverse events[1]. However, adverse events from this procedure are associated with increased morbidity and mortality. The most common being bleeding, AKI, procedure induced mitral stenosis, pericardial effusion, and structural device failure/ leaflet injury. Mitral clip single leaflet detachment (SLD) is a mechanism of failure which typically results in severe MR in 1.0%- 1.5% of mitral clip procedures in the US[2]. Repeated mitral clip insertion after prior SLD is associated with low success and typically results in a need for surgical intervention. Typically, persistent MR or SLD with low transmitral gradient can be considered for a reclip procedure however severe leaflets injury can exclude the patient from

reclipping[1]. Given this patients presentation of symptomatic severe MR after SLD from the first mitral clip, reclipping using procedural echo deemed to be successful with no complications and an uneventful hospital stay versus the alternative high risk surgical approach. In certain patient populations that may be high risk surgical candidates, repeat mitral clip insertion after a single leaflet rupture, can be deemed successful as in this case.

(1) Schnitzler K, Hell M, Geyer M, Kreidel F, Münzel T, von Bardeleben RS. Complications Following MitraClip Implantation. *Curr Cardiol Rep*. 2021;23(9):131. Published 2021 Aug 13. doi:10.1007/s11886-021-01553-9

(2) Huded CP, Kapadia S, Horr S, et al. Management of MitraClip Single-Leaflet Detachment with an Additional Clip and an Amplatzer Vascular Plug. *JACC Case Rep*. 2019;1(5):755-760. Published 2019 Dec 18. doi:10.1016/j.jaccas.2019.10.020

Title: Broken Wing: Mechanical Leaflet Failure After Aortic Valve Replacement

Authors: Rebecca Mutesi Balimunkwe, M.D., Raymond Malapero, M.D., M.P.H, and Deepak Singh, M.D.

Introduction:

Mechanical valve leaflet failure after surgical implantation is uncommon and can be acute or chronic in presentation. Possible reasons for leaflet failure are thrombosis, calcium deposits, leaflet fracture and migration[iii], and endocarditis. Options for management depend on the nature of the mechanical leaflet failure and the clinical picture. Here we describe a case in which one leaflet failed 10 years after initial aortic valve replacement and was successfully managed with a redo aortic valve replacement.

Case Report:

PMH

An 82-year-old woman with a past medical history of hypertension, hyperlipidemia, normal left ventricular ejection fraction, bilateral carotid artery stenosis, and a mechanical aortic valve replacement 10 years ago performed out of state. She recently moved to New Jersey and began having shortness of breath with exertion three months ago. A transthoracic echocardiogram performed by her cardiologist revealed that one of the mechanical valve leaflets was stuck closed causing severe aortic stenosis (with peak pressure exceeding 100 mmHg) and moderate aortic insufficiency.

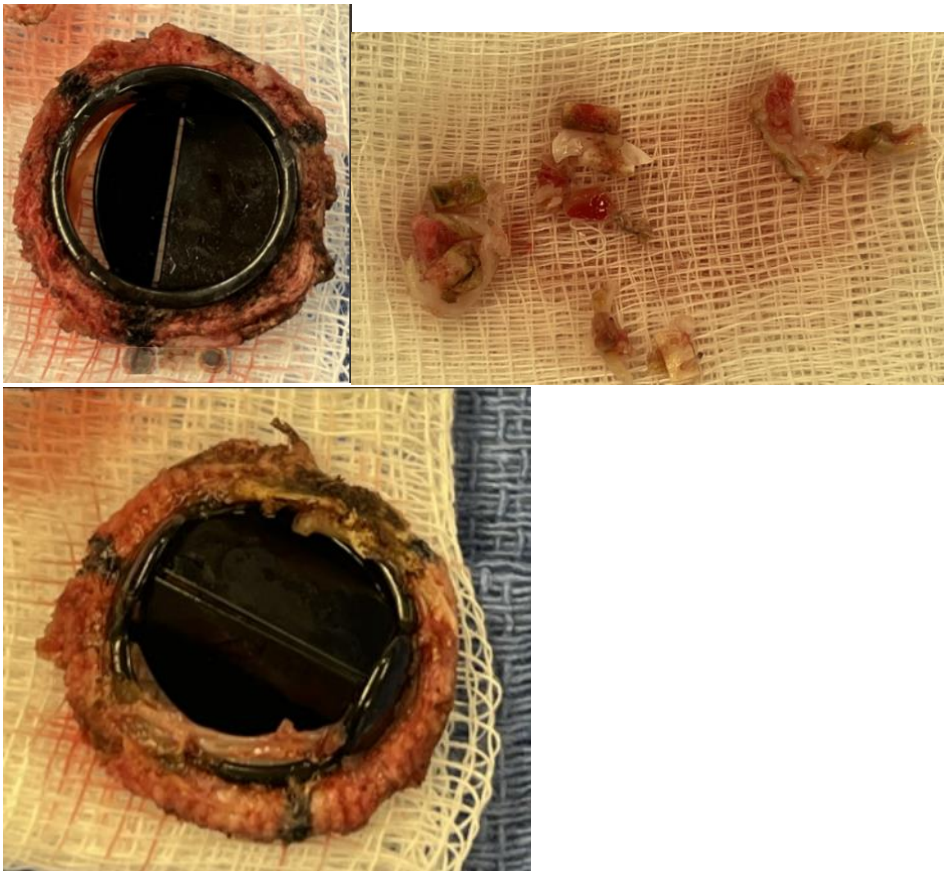

Figure 2. Defective Valve

The patient was offered carotid surgery, but declined it. She was then booked for redo aortic valve replacement. She underwent uneventful induction of anesthesia with midazolam, fentanyl, propofol, phenylephrine, lidocaine, and rocuronium. The surgical team obtained further access including cannulating the femoral artery and vein, and 7-french catheters were placed in case of emergent need for extracorporeal membrane oxygenation (ECMO) during redo-sternotomy.

After an uneventful sternotomy, the aortic valve was replaced with a bioprosthetic valve that would allow for future transcatheter aortic valve replacement (TAVR), if needed. Repair was successful and the patient was weaned easily off of bypass with dobutamine. TEE demonstrated a hyperdynamic ventricle. The patient was transferred to the ICU and successfully extubated later that afternoon. From a clinical standpoint, she was neurologically intact, able to be weaned off vasopressors, and was transferred to step down the following day.

Discussion:

The learning point here is that mechanical valve leaflet failure can occur. Here, it occurred 10 years after the original AVR. Options for management can vary including medical options such as thrombolysis versus surgery[iii]. In our case, aortic valve leaflet failure was managed successfully with redo AVR while allowing for future intervention options, if necessary.

References:

[i] Helgeland, E, Andresen, K, Dumont, K.A., & Bjornstad, J.L. "Leaflet fracture and embolization from an On-X mechanical mitral valve." JTCVS Techniques. Volume 3, Number C. September 2020.

[ii] Eldreth, B., Hadijizacharia, P., & Feuer, D. "Embolized mechanical aortic valve leaflet causing infrarenal aortic stenosis and claudication." Journal of Vascular Surgery Cases, Innovations and Techniques. December 2020. Volume 6, Issue 4. Pages 534-538.

[iii] Salamon, J., Munoz-Mendoza, J., Liebelt, J.J., & Taub, C.C. Mechanical valve obstruction: Review of diagnostic and treatment strategies. World J Cardiol. 2015 Dec 26; 7 (12) 875-881.

Intraoperative Reading Policies: A National Survey of Residency Program Directors

Steven Char, M.D., James Schiffenhaus, M.D. Rotem Naftalovich, M.D Michal Gajewski D.O.
Department of Anesthesiology & Perioperative Medicine, Rutgers – New Jersey Medical School, Newark, New Jersey

Background

- Perioperative distractions are categorized as externally imposed (e.g. OR noise, music, case-irrelevant conversation) or internally motivated (e.g. personal-electronic-devices [PED] and reading)[1]
- These distractions are widespread and may pose a threat to anesthesiologists as they deliver care.
- With an increase in our dependency on PEDs over the last two decades, it is important to investigate whether the use of this technology has an adverse effect on patient care.
- **Aim**: To gain further understanding on whether institutions have intraoperative reading policies and whether PED use among anesthesia providers has beneficial, detrimental, or no effect on patient care.

Methods

- An IRB-approved ten-question survey was sent to 148 Accreditation Council for Graduate Medical Education (ACGME) accredited anesthesiology residency programs
- A total of 23 survey responses were received over the span of two months.

Results

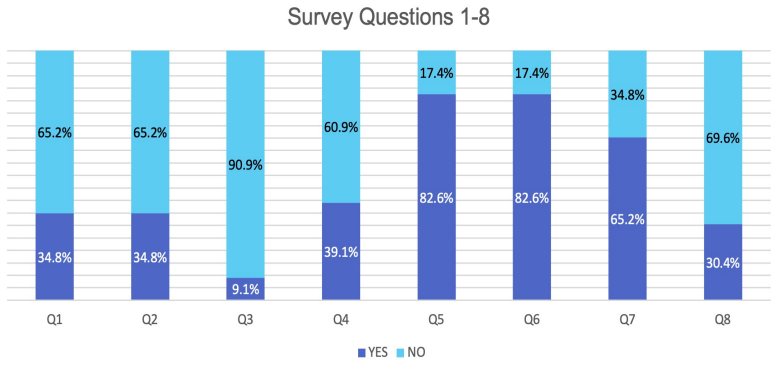

- Q1: Does your department have an intraoperative reading policy?
- Q2: Does your hospital have an intraoperative policy on mobile devices or personal-electronic-
- devices (PEDs)
- Q3: Have there been any adverse patient outcomes as a direct result of PED use?
- Q4: Does your program reimburse residents for purchasing electronic media devices?
- Q5: Do you educate your residents on proper use of PEDs around patient care?
- Q6: Does your program pay for online question banks for residents?
- Q7: Do you think intraoperative reading promotes a negative public image of anesthesia providers?
- Q8: Have you encountered issues with noncompliance?

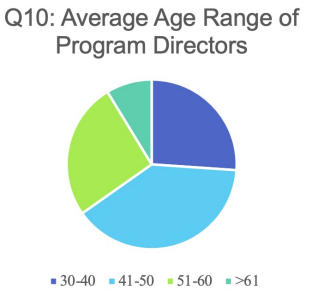

Discussion

- Situational awareness is considered one of the most important factors in providing quality patient care[3].
- Perception (influenced by cognitive workload, physician expertise, and distractions) is the level where the majority of situational awareness errors occur[4,5].
- PEDs can have a beneficial role for anesthesiology residents by providing on-the-go access to educational material (Q6).
- However, use of PEDs also have the potential of causing adverse patient outcomes in the perioperative setting (Q3).

Conclusion

- Results from our survey support the perspective that, although not a common occurrence, PEDs have the potential of causing adverse patient outcomes.
- This begets the question: Should all residency programs have policies directed towards PED use and if so, what is the best way to enforce them?

Scan for Rutgers NJMS Intraoperative Reading Policy

SCAN ME

References

1. Gui JL, Nemergut EC, Forkin KT. Distraction in the operating room: A narrative review of environmental and self-initiated distractions and their effect on anesthesia providers. *J Clin Anesth*. 2021;68:110110. doi:10.1016/j.jclinane.2020.110110
2. Slagle JM, Weinger MB. Effects of intraoperative reading on vigilance and workload during anesthesia care in an academic medical center. *Anesthesiology*. 2009;110(2):275-283. doi:10.1097/ALN.0b013e318194b1fc
3. Endsley MR. Design and Evaluation for Situation Awareness Enhancement. Proceedings of the Human Factors Society Annual Meeting. 1988;32(2):97-101. doi:10.1177/154193128803200221
4. Schulz CM, Endsley MR, Kochs EF, Gelb AW, Wagner KJ. Situation awareness in anesthesia: concept and research. *Anesthesiology*. 2013;118(3):729-742. doi:10.1097/ALN.0b013e318280a40f
5. Schulz CM, Burden A, Posner KL, et al. Frequency and Type of Situational Awareness Errors Contributing to Death and Brain Damage: A Closed Claims Analysis. *Anesthesiology*. 2017;127(2):326-337. doi:10.1097/ALN.0000000000001661
6. Byrne AJ, Oliver M, Bodger O, et al. Novel method of measuring the mental workload of anaesthetists during clinical practice. *Br J Anaesth*. 2010;105(6):767-771. doi:10.1093/bja/aeq240

IV Acetaminophen vs. Placebo Administration and Stress Response in Patients Undergoing Laparoscopic Cholecystectomy

RUTGERS
New Jersey Medical School

Steven Char, M.D., Kwame Awuku, M.D., Michal Gajewski D.O.

Department of Anesthesiology & Perioperative Medicine, Rutgers – New Jersey Medical School, Newark, New Jersey

Background

- Acetaminophen is one of the most widely used medications for pain and fever in the United States.
- There has been a rise in the use of non-opioid medications as part of a multimodal approach to acute pain.
- The ERAS protocols aims to decrease the perioperative stress response, achieve early return of organ function and create safe and cost-effective methods leading to prompt patient discharge[1].
- Although PO acetaminophen has been claimed to lack anti-inflammatory properties, we wanted to investigate if this lack of effect extended to IV acetaminophen and other stress markers.
- **Hypothesis**: The preemptive and Q4hr dosing of IV acetaminophen would lead to a decrease in surgical stress response.

Methods

- An IRB-approved, double-blinded, randomized, placebo-controlled, two-arm parallel trial. Total of 65 participants (34 in study group and 31 in placebo group).
- Subjects included: male and female, over the age of 18, undergoing same-day laparoscopic cholecystectomy with an ASA classification of 1 to 3.
- Blood samples (15ml) for the analysis of cortisol, C-reactive protein (CRP), cytokines (IL-6, IL-8, and IL-10), epinephrine, and norepinephrine were collected at 3 different time points: before administration of any drug (after placement of IV lines), before incision, and 60 minutes after arrival in PACU.

Results

Table 1: Distribution of Biomarkers and Comparison Across Treatment Arms and Time

	Acetaminophen: Median Concentration (IQR)			Placebo: Median Concentration (IQR)			P-value: Arm * Time
Biomarker	After IV	In OR	In PACU	After IV	In OR	In PACU	
IL-6	2.6 (1.6)	2.2 (1.3)	12 (12)	1.7 (0.9)	1.8 (1.0)	12 (21)	0.27
IL-8	8.8 (4.2)	7.1 (3.5)	21 (25)	12 (18)	8.8 (9.0)	20 (22)	0.77
IL-10	1.1 (0.8)	1.1 (0.6)	3.2 (3.9)	0.8 (0.5)	0.8 (0.5)	4.4 (7.1)	0.74
CRP	2054 (1608)	1913 (1581)	1745 (1603)	1913 (1771)	1569 (1650)	1697 (1769)	0.99
Cortisol	62 (44)	61 (47)	139 (65)	57 (30)	60 (46)	148 (69)	0.64
Epinephrine	690 (310)	623 (302)	902 (505)	718 (299)	551 (273)	810 (489)	0.4
Norepinephrine	83 (97	68 (49)	182 (195)	67 (52.2)	45 (34)	210 (228)	0.4

Note: Median (IQR) concentration (pg/ml) reported for all biomarkers except CRP which is pg/L Differences in biomarkers across time and treatment arm were tested using a repeated measures MANOVA. The main effect of time was significant for all biomarkers (p<0.0001) but the main effect of treatment arm and the interaction between treatment and time were not significant for any biomarker

Figure 1: Biomarker Levels After IV Placement, in OR, and in PACU

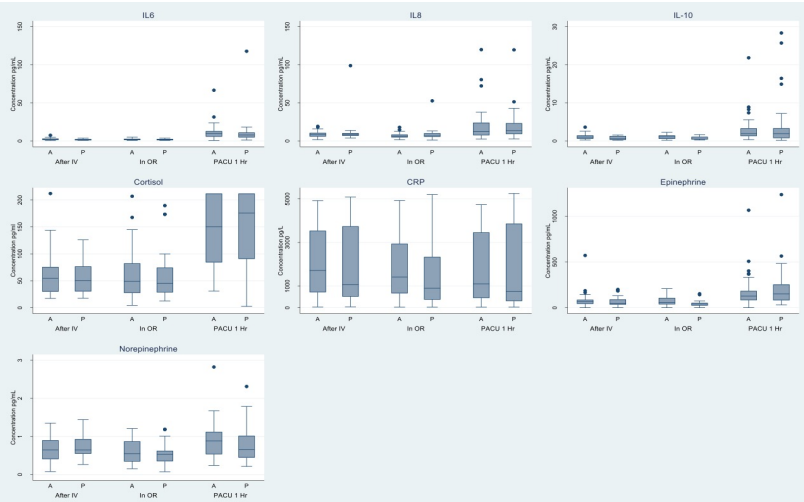

A= Acet; P= Placebo

Discussion

- Cytokines usually increase relative to the tissue trauma experienced during surgery.
- IL-6 and IL-8 began to increase after incision, peaked rapidly, and returned to baseline within 24 hours.
- IL-10 usually increases right after incision and peaks 3-4 hours later[2] which is perhaps why we did not see a rise in either of the study arms.
- CRP is mediated by IL-6 and peaks 20-30 hours after surgical stimulation; however, our samples showed a decrease from baseline during the surgical procedure, with the study group showing a greater decline (309 mcg/dl vs 216 mcg/dl) than placebo.
- Plasma cortisol levels increased in both cohorts with a slightly lower increase in the study arm (77 mcg/dl vs 91 mcg/dl). This could be attributed to the fact that acetaminophen is known to decrease cortisol levels by inhibiting the CYP17A1 enzyme[3].
- Consistent with previous reports[4] both epinephrine and norepinephrine increased after skin incision.

Conclusion

- Among patients undergoing laparoscopic cholecystectomy, the use of pre-emptive and Q4 hour dosing of intravenous acetaminophen still showed elevations in IL-6, IL-8, IL-10, Cortisol, Epinephrine, and Norepinephrine.
- CRP levels decreased greater in the study group than placebo.
- No statistically significant difference was noticed among the two arms.

References

1. Kaye, A.D., Urman, R.D., Rappaport, Y., Siddaiah, H., Cornett, E.M., Belani, K., Salinas, O.J. and Fox, C.J., 2019. Multimodal analgesia as an essential part of enhanced recovery protocols in the ambulatory settings. *Journal of anaesthesiology, clinical pharmacology*, *35*(Suppl 1), p.S40.
2. Kato, M., Honda, J., Suzuki, H., Murakami, M., Matsukawa, S. and Hashimoto, Y., 1998. Interleukin-10 production during and after upper abdominal surgery. *Journal of clinical anesthesia*, *10*(3), pp.184-188.
3. Oskarsson, A., Ullerås, E. and Ohlsson Andersson, Å., 2016. Acetaminophen increases aldosterone secretion while suppressing cortisol and androgens: a possible link to increased risk of hypertension. *American journal of hypertension*, *29*(10), pp.1158-1164.
4. Le, V., Kurmutala, L., Schiano Di Cola, J., Ahmed, K., Yarmush, J., Daniel Eloy, J., Shapiro, M., Haile, M. and Bekker, A., 2016. Premedication with intravenous ibuprofen improves recovery characteristics and stress response in adults undergoing laparoscopic cholecystectomy: a randomized controlled trial. *Pain Medicine*, *17*(6), pp.1163-1173.

Title: **Case Cancellations in the Operating Room**

Authors: *Renee McDonald-Fleming, MD; Kathryn Ticehurst, MD, MA; Priscilla Owusu, MD; Anthony Irungu, MD; Nikhil Kaushal, MD; George Tewfik, MD, BA, CPE.*
Department of Anesthesiology; Rutgers – New Jersey Medical School, Newark, New Jersey

Presenter: Renee McDonald-Fleming, rtm118@njms.rutgers.edu, 347-581-8422

Unplanned surgery cancellation (USC) is a widespread problem for healthcare organizations. Cancellations have a significant impact on both healthcare systems and patients with psychological, social, and financial implications. In addition, operating room resources were wasted due to USC of virtual surgery patients. Patient and family complaints include repeated visits to the hospital before surgery, inadequate preoperative evaluation, and surgery cancellation which negatively impact the patient experience and quality of care which require urgent improvement.

There have been several studies within single institutions, showing that the incidence of USC was higher than 10% and up to 40% in low- and middle-income countries. A 2020 meta-analysis involving 306,635 case cancellations throughout the world (with a majority of Latin American and African studies) suggested that the global prevalence of cancellation on the operative day was approximately 18% and that USC was the greatest contributor to OR inefficiency. Results of the meta-analysis found the top reason for cancellation was lack of available operating facility, followed by patient absence on day of surgery and change in medical condition [1].

A large-scale study of case cancellations in Veteran's Administration hospitals across America was conducted in 2009. Interestingly, one of the difficulties encountered in the study was appropriately classifying cases. Though the VA system employs a fixed set of 13 case cancellation reasons, site-specific editing capabilities resulted in nearly 10,000 reasons for cancellation from the 370,000 cases that were included. Because of the overwhelming number of reasons for cancellation found, this necessitated the creation of a standard set of 28 cancellation reasons within the study. Cancellations in this study were assigned to one of 6 categories: patient (35%), work-up/medical condition change (28%), facility (20%), surgeon (8%), anesthesia (1%), and miscellaneous (8%) [2]. Proper

classification of case cancellations at University Hospital was also inherently flawed given inaccurate classification of cancellations and reliance on nursing staff documentation for data collection.

While there are many confounding variables in studying unplanned cancellations, especially regional differences in population socio-economics, it is clearly a worldwide issue that has tremendous ramifications on the local level. As ORs generate a significant portion of hospital revenue, inefficiency in this department has far-reaching effects beyond the immediate costs to staff and patients. As already discussed, it is crucial that a streamlined and reliable classification system be implemented to address the inefficiencies that we see on a daily basis at University Hospital.

Title: **How Lung Before It's Too Late**

Authors: Renee McDonald-Fleming MD, Shivani Patel DO , Priscilla Owusu MD , Ming Xiong MS, MD/PHD

Department of Anesthesiology; Rutgers – New Jersey Medical School, Newark, New Jersey

Presenter: Renee McDonald-Fleming, rtm118@njms.rutgers.edu, 347-581-8422

Trauma remains a leading cause of death across all age groups, with thoracic injuries contributing to at least half of these. About 10% of blunt injuries and 25% of penetrating injuries will need emergent thoracotomy. This makes it crucial for surgical and anesthetic teams to cohesively resuscitate a patient in a timely and coordinated function. The reason for thoracic injury is often not known until the intraoperative period. The resuscitative goal of the anesthesiologist is to anticipate injuries that impair oxygenations such as, airway injury (0.8%), pneumothorax (23% of trauma injuries), pulmonary contusion-flail chest complex (25-35% of blunt chest trauma), and diaphragmatic injury; as well as maintaining hemodynamic indices from cardiovascular anatomy injuries that impair perfusion in an already hypovolemic patient. These include right ventricular injuries that lead to arrythmia, obstructive cardiac shock (tamponade, hemothorax), and aortic injuries (highest mortality). Given the fatality of these injuries it is imperative to secure the airway and apply appropriate mode of ventilation to ensure appropriate oxygenation primarily in our anesthetic management. Appropriate ventilation often means lung isolation during rapid sequence intubation in these cases (⅓ failure rate) - particularly during active suspected hemorrhage. The following case demonstrates some of the intraoperative complications that can occur when this component of our anesthetic management is delayed.

Title: **How Lung Before It's Too Late**

Authors: Renee McDonald-Fleming MD, Shivani Patel DO , Priscilla Owusu MD , Ming Xiong MS, MD/PHD

Department of Anesthesiology; Rutgers – New Jersey Medical School, Newark, New Jersey

Presenter: Renee McDonald-Fleming, rtm118@njms.rutgers.edu, 347-581-8422

Trauma remains a leading cause of death across all age groups, with thoracic injuries contributing to at least half of these. About 10% of blunt injuries and 25% of penetrating injuries will need emergent thoracotomy. This makes it crucial for surgical and anesthetic teams to cohesively resuscitate a patient in a timely and coordinated function. The reason for thoracic injury is often not known until the intraoperative period. The resuscitative goal of the anesthesiologist is to anticipate injuries that impair oxygenations such as, airway injury (0.8%), pneumothorax (23% of trauma injuries), pulmonary contusion-flail chest complex (25-35% of blunt chest trauma), and diaphragmatic injury; as well as maintaining hemodynamic indices from cardiovascular anatomy injuries that impair perfusion in an already hypovolemic patient. These include right ventricular injuries that lead to arrythmia, obstructive cardiac shock (tamponade, hemothorax), and aortic injuries (highest mortality). Given the fatality of these injuries it is imperative to secure the airway and apply appropriate mode of ventilation to ensure appropriate oxygenation primarily in our anesthetic management. Appropriate ventilation often means lung isolation during rapid sequence intubation in these cases (⅓ failure rate) - particularly during active suspected hemorrhage. The following case demonstrates some of the intraoperative complications that can occur when this component of our anesthetic management is delayed.

Methods (Case Report Review)

This is the case of a 30 year old male, who was found on the sidewalk by emergency medical services (EMS) after presumed assault or self-inflicted injury. Per EMS, patient was not breathing well and had blood coming from bilateral ears. Intubation was attempted in the field after which he developed asystole, due to suspected esophageal intubation. Cardiopulmonary resuscitation was started, patient was

reintubated, and return of spontaneous circulation was achieved after two rounds of epinephrine. Upon arrival to the emergency department, patient was tachycardic and hypotensive with findings of crepitus on the right chest wall. A chest tube was placed with 150 mL of blood was drained in addition to a gush of air. Rapid bedside ultrasound exam was positive in the splenorenal pouch, therefore massive transfusion protocol (MTP) was started. Patient was then taken for emergent computed tomography (CT) of the head, followed by emergent exploratory laparotomy in the operating room.

Upon arrival to the OR, HR was 127, BP 91/57 via noninvasive cuff, SpO2 93% on 100% FiO2. Patient was given phenylephrine and ephedrine boluses, started on isoflurane inhaled agent at 0.3% end-tidal concentration with progressing hypotension and hypoxia. At this point, patient was given 5 mg midazolam and 50 mg rocuronium for paralysis. After adequate intravenous access was obtained, an arterial line was placed, epinephrine drip was started and titrated to a goal mean arterial pressure (MAP) of 65. Initial arterial blood gas (ABG) revealed arterial oxygen concentration (PaO2) of 65 on 100% inspired oxygen (FiO2) and hematocrit 20%. MTP was continued during the surgery with eight units packed red blood cells (pRBC) and seven units fresh frozen plasma (FFP), 1 unit pooled platelets given until the patient was weaned off of

epinephrine drip. Intraoperative exploratory laparotomy findings revealed right lobe liver laceration and expanding hematoma by the renal hilum, both of which were repaired. The abdomen was left open with temporary closure. Towards the end of the case, it was noted by the anesthesia team that the patient began to have increased thin bloody secretions from ETT and peak airway pressures were trending up since the start of surgery out of proportion to increase in PEEP. A brief discussion was had between the anesthesia and surgical teams regarding the possibility of intrathoracic pathology and a plan for chest CT was made per surgery. ABG just prior to leaving the OR showed PaO2 74 and hematocrit 25%. During transport out of the OR, patient became hypoxic with subsequent hypotension. The right chest tube also noted to have increased drainage (~1 L) after milking the tubing. Patient was brought immediately back to the operating room. Massive transfusion protocol was restarted, along with epinephrine drip. It was noted on the ventilator, continued increased airway pressure with increasing difficulty achieving appropriate tidal volumes. At this point, a bronchoscopy was performed by the anesthesia team with a disposable scope that showed right blood in the right lobe without any large mucous plugging; this procedure was terminated due to patient inability to tolerate it. Intraoperative immediate chest x-ray revealed massive hemothorax previously not present and therefore decision for thoracotomy was made by the surgical team. Oxygen saturations remained in mid-80's and patient did not tolerate attempted placement of

bronchial blocker under fiberoptic guidance with a nadir saturation of 50%. Thus, surgery was continued with two lung ventilation.

Thoracotomy findings revealed a large right middle lobe lung laceration due to multiple displaced rib fractures. Patient continued to be hypotensive throughout requiring epinephrine drip and additional epinephrine boluses. Following repair of laceration, continuation of MTP with a 1:1:1 ratio of pRBC, FFP, and platelets, patient eventually stabilized and was weaned off of vasopressors prior to transport out of the operating room. Final airway pressures were still elevated but improved from prior and PaO2 was 91 on 100% FiO2.

Conclusion

The case above underscores the importance of anesthetic management in facilitating surgical interventions especially in fast paced trauma scenarios. Anchoring on anesthetic fundamentals of hemodynamic management and ventilatory support not only serve to resuscitate the patient but they can also help to provide insight for our surgical colleagues about patient pathology. It is important to make sure that we actively explore all differentials when treating patients to make sure the underlying pathology isn't missed. During high stress trauma situations, it is very easy to become overwhelmed with the many aspects of the case from aggressive fluid resuscitation, placing lines, invasive monitor and managing hemodynamics. As a result, important components of anesthetic management can be overlooked. In this case there was a delay in implementing one lung ventilation (OLV).

One lung ventilation (OLV) is a useful technique employed for a multitude of reasons with active pulmonary hemorrhage being an absolute indication. Familiarity and comfort level with double-lumen tubes and bronchial blockers are pivotal in deciding which one to use especially in a trauma setting. Although the primary principle behind OLV in this setting involves the use of hypoxic pulmonary vasoconstriction to improve ventilation/perfusion matching, some patients may not tolerate the procedure.

In addition to aggressive resuscitation with appropriate blood products, it is equally important to investigate the reasons behind a clinical scenario. As mentioned earlier, in high acuity situations it is easy to get fixated on a specific diagnosis. In this case, it was assumed the primary source of bleeding was intra-abdominal and this was further supported by the temporary stabilization occurring after surgical correction. However, had we recognized the high likelihood of large intrathoracic hemorrhage earlier, perhaps early OLV would have prevented the steep decline in hemodynamic status. Guidelines suggest that tube thoracotomy be used in instances of penetrating chest trauma where there patient is unstable despite appropriate fluid resuscitation or has been receiving CPR for <15 minutes. Indications for use to thoracotomy in blunt

trauma remain controversial despite guidelines recommending against its use, studies have found that greater than 50% of providers still perform the procedure. This could be due to the fact that the tendency for a greater delay in blunt injuries may be associated with worse outcomes. There is some data to support thoracic bleeding >1500 mL within the first 24h of injuries, regardless of whether the inciting mechanism is blunt or penetrating, should warrant thoracotomy [11].

In this case, with a chest tube output of of 1 L during transport in the presence of hemodynamic compromise should have been cause enough for immediate operative intervention. Perhaps implemented earlier OLV may have been better tolerated in this patient, however without control of the source of bleeding the likelihood of eventual decompensation still remained high. In the setting of multiple unknown injuries and tenuous cardiopulmonary status, vigilance, open communication and discussions between the anesthesia and surgical teams is crucial in determining patient outcomes.

References

1. Duan Y, Smith CE, Como JJ. Cardiothoracic trauma. In: Wilson WC, Grande CM, Hoyt DB, editors. Trauma. Volume 1. Emergency resuscitation, perioperative anesthesia and surgical management. New York: Informa Healthcare; 2007. pp. 469–499. Multiauthored textbook discussing management of the trauma patient from the prehospital phase to the operating room. This chapter includes imaging, lung isolation techniques and options for postoperative analgesia.

2. Meredith JW, Hoth JJ. Thoracic trauma: when and how to intervene. Surg Clin North Am 2007; 87:95–118. Describes injury patterns and surgical decision-making processes in relation to timing and anatomical approaches for thoracic trauma patients.

3. Devitt JH, McLean RF, Koch JP. Anaesthetic management of acute blunt thoracic trauma. Can J Anaesth 1991; 38:506–510.

4. Kummer C, Netto FS, Rizoli S, Yee D. A review of traumatic airway injuries: potential implications for airway assessment and management. Injury 2007; 38:27–33. Describes clinical presentations of a series of 104 patients with airway injuries, with discussion of the clinical implications, particularly with regard to airway management

5. Purohit, Atul et al. "Lung isolation, one-lung ventilation and hypoxaemia during lung isolation." Indian journal of anaesthesia vol. 59,9 (2015): 606-17. doi:10.4103/0019-5049.165855

6. Campos, Javier H, and Andrew Feider. "Hypoxia During One-Lung Ventilation-A Review and Update." Journal of cardiothoracic and vascular anesthesia vol. 32,5 (2018): 2330-2338. doi:10.1053/j.jvca.2017.12.026

7. Karzai, Waheedullah, and Konrad Schwarzkopf. "Hypoxemia during one-lung ventilation: prediction, prevention, and treatment." Anesthesiology vol. 110,6 (2009): 1402-11. doi:10.1097/ALN.0b013e31819fb15d

8. Bonatti, Hugo, and James Forrest Calland. "Trauma." Emergency medicine clinics of North America vol. 26,3 (2008): 625-48, vii. doi:10.1016/j.emc.2008.05.001

9. Ohrt-Nissen, S et al. "Indication for resuscitative thoracotomy in thoracic injuries-Adherence to the ATLS guidelines. A forensic autopsy based evaluation." Injury vol. 47,5 (2016): 1019-24. doi:10.1016/j.injury.2015.10.034

10. Mollberg, Nathan M et al. “Appropriate use of emergency department thoracotomy: implications for the thoracic surgeon.” The Annals of thoracic surgery vol. 92,2 (2011): 455-61. doi:10.1016/j.athoracsur.2011.04.042

11. Karmy-Jones R, Jurkovich GJ, Nathens AB, et al. Timing of Urgent Thoracotomy for Hemorrhage After Trauma: A Multicenter Study. Arch Surg. 2001;136(5):513–518. doi:10.1001/archsurg.136.5.513